


Complete separation of the urinary tract from proximal rectum during PSARP surgery: our experience with the novel technique

Md Samiul Hasan , Md Nazmul Islam, Refoyez Mahmud, Umama Huq, Ashrarur Rahman

To cite: Hasan MS, Islam MN, Mahmud R, et al. Complete separation of the urinary tract from proximal rectum during PSARP surgery: our experience with the novel technique. *World J Pediatr Surg* 2024;7:e000688. doi:10.1136/wjps-2023-000688

Received 22 August 2023
Accepted 26 December 2023

Anorectal malformation (ARM) is a frequently occurring surgical condition in neonates, with a prevalence of 1 in 4000 live births.¹ In boys with this anomaly, the rectum and urinary tract share a common wall for some distance, often ending up in fistulous communication. The goals of definite reconstruction are to separate the rectum from the urinary tract without injuring the urethra and mobilizing the rectum to the perineum within the muscle complex. Separating the rectum and the urinary tract is the most critical part of this operation and is associated with a significant risk of urinary tract injury.²⁻⁵ The original procedure described by Peña and Devries involves multiple stay sutures on the rectal mucosa just above the fistula, lifting the mucosa and continuing a submucosal dissection up to the prostate, where the entire thickness of the intestine can be separated from the urinary tract.⁶ These stay sutures have the inherent risk of incorporating the urethra within and thereby injuring the urethra. Moreover, this submucosal dissection is delicate and requires master's expertise to avoid urethral injury, which frequently occurs in boys with relatively benign lower malformation.

However, a relatively significant space separates the rectum and the urinary tract proximal to the common sharing wall ([figure 1](#)). By first mobilizing the rectum proximally in an antegrade fashion and lifting it from the urinary tract with a loop, the posterior wall of the urethra, prostate, and bladder is easily visible. This also establishes a clear boundary between the rectum and urinary tract, making it possible to resect the fistula precisely without needing a traction suture.

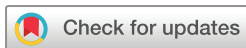We reviewed the medical records of patients who underwent posterior sagittal

anorectoplasty (PSARP) for ARM between March 2021 and March 2023. The minimum follow-up was 3 months. Demographic and clinical data were recorded in a predesigned form.

We excluded boys who needed an extra-abdominal approach for a higher fistula and boys who did not have a urethral fistula. Those who had a prior PSARP in different centers and underwent reoperation due to complications were also excluded.

All patients had a colostomy in situ. Detailed clinical examinations and investigations were performed to identify coexisting anomalies. A high-pressure distal colostogram was performed to locate the fistula for every patient. The sacral index was measured and recorded. Informed written consent was obtained from the legal guardian after discussing the operative procedure.

After induction of anesthesia, patients were catheterized and placed in the prone position. The sphincter area was identified by a muscle stimulator and was marked by silk sutures. A posterior sagittal incision was made in the midline, as described by Peña and Devries.⁶ After identifying the rectal pouch, we dissected the prerectal fascia and continued the dissection laterally and proximally within the rectal fascia. The rectal pouch was then opened in the midline between the stay sutures up to the fistula opening ([figure 2A](#)). Next, Moynihan forceps were used to carefully mobilize the rectum circumferentially within the prerectal fascia, proximal to the fistula. Staying within this area is crucial in preventing harm to the genitourinary nerves in the retrovesical space ([Figure 2B](#)). The rectum was lifted, and the urethra was pulled down using two loops. This allowed a clear distinction between the rectum and the urethra. The rectum was



© Author(s) (or their employer(s)) 2024. Re-use permitted under CC BY-NC. No commercial re-use. See rights and permissions. Published by BMJ.

Pediatric Surgery, Bangladesh Shishu Hospital and Institute, Dhaka, Bangladesh

Correspondence to
Dr Md Samiul Hasan;
samiulo45@gmail.com

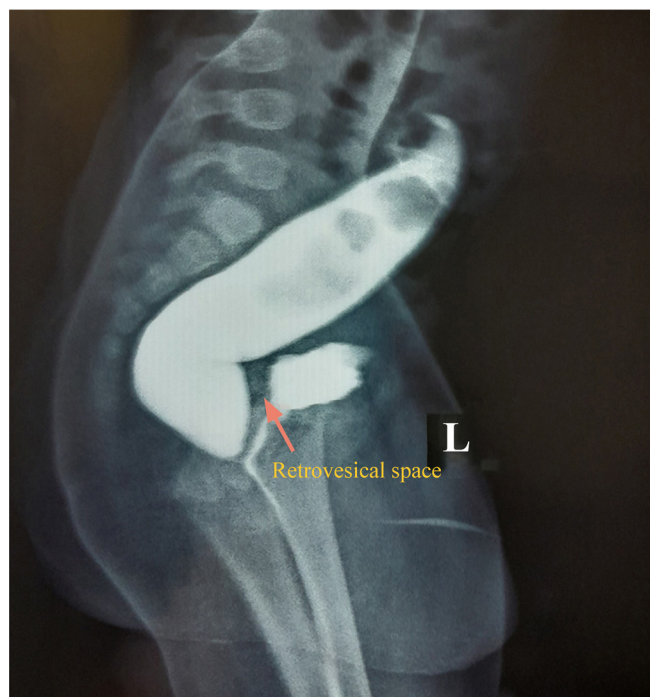

Figure 1 Distal loopogram showing retrovesical space.

then separated from the urethra under direct vision (figure 2C). The urethra was closed with a 2/3 interrupted suture. The rectum was then mobilized enough to bring it to the perineum within the sphincter complex without undue tension. After the anoplasty, the wound was closed in layers. A Foley catheter was kept in the bladder for 24 hours. The patients were discharged home on the third or fourth postoperative day and advised to follow-up after 15 days. On follow-up, the caliber of the neoanus was checked. When adequate, parents were advised for colostomy closure after 3 months, and when not acceptable, parents were advised to consider dilation with a Hegars dilator followed by colostomy closure.

During the study period, 51 boys underwent PSARP in our department. Of them, 13 boys had no fistula, 7 required an additional abdominal approach for a higher fistula, and 11 underwent reoperation for postoperative

rectourethral fistula (RUF) (they were referred to us from other centers with recto urinary fistula after PSARP). The remaining 20 boys underwent PSARP with resection of the RUF with the modified technique. Among these 20 boys, 16 had a recto bulbar urethral fistula, and 4 had a rectoprostatic urethral fistula. The mean age at operation was 13.4 ± 9.7 months. Fourteen patients (70%) had coexisting anomalies, with cardiac anomalies being the highest in frequency ($n=11$, 55%), although they did not require surgical correction. One patient had type 1 ileal atresia, which was corrected during colostomy for ARM. Two boys underwent orchiopexy for undescended testis, one boy underwent urethroplasty, and one boy received correction of talipes equinovarus.

The mean operation time was 67.2 ± 7.7 min. The RUF was resected in all boys, and the rectum was completely separated from the urinary tract. None of the boys had short-term or long-term urological complications. None of the patients had wound infection, dehiscence, or neoanal prolapse. It was not recommended for the parents to perform neoanal calibration regularly. The attending surgeon conducted monthly assessments of neoanal adequacy after the PSARP surgery until stoma reversal. Three patients developed neoanal stenosis, effectively treated with dilation using the Hegars dilator.

Over 80% of boys with ARM have RUF, which is a major challenge for surgeons due to the shared wall between the rectum and urethra, resulting in frequent injury-related urethral complications during PSARP.⁵⁻⁷ However, modifications to the original PSARP have been reported to reduce urinary injury and complications. For example, Huang *et al* suggested performing cystoscopy before PSARP to place a ureteral catheter through the fistula into the rectum.⁷ Stenström *et al* placed an endoscopy-guided guide wire through the stoma into the fistula.⁸ These procedures make it easier to identify fistulas and reduce urethral complications. Nevertheless, they require an extra procedure, increased operation time, and longer anesthesia and pose a risk of contamination. Moreover, these modifications do not reduce the risk of urethral injury during fistula resection. It is not

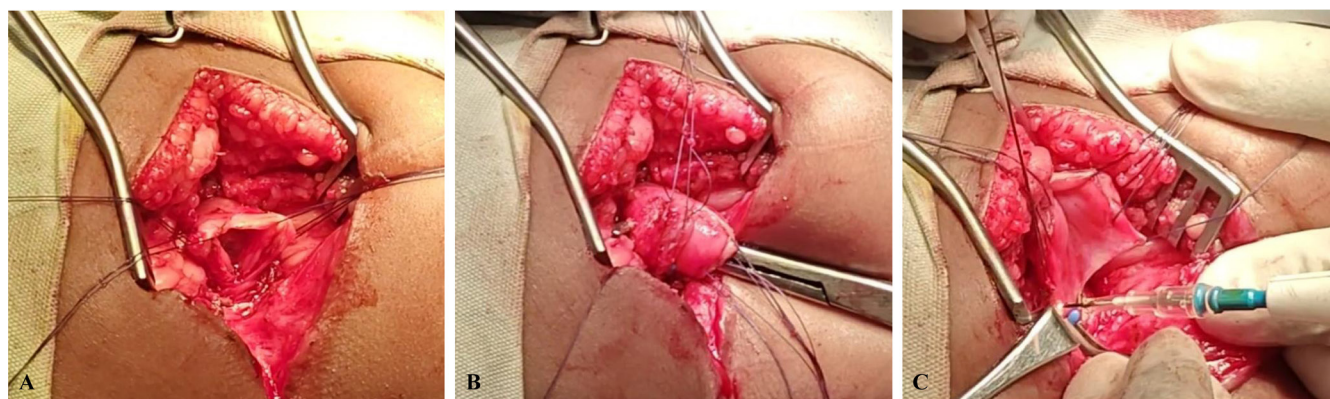

Figure 2 Surgical technique. (A) opening the rectal pouch in the midline; (B) proximal mobilization of the rectum and dissection of the retrovesical space with a Moynihan forcep; (C) proximal mobilization of the rectum and dissection of the retrovesical space with a Moynihan forcep.

our standard practice to routinely carry out cystoscopy or endoscopy in our setup, and our average operating time was lower than that in other studies.⁹

The most crucial step in the procedure is separating the fistula, not identifying it. Using a high-pressure distal loopogram with radiological mapping, the fistula can be easily identified at the terminal end or anterior surface of the intestine.⁶ Our modified technique includes upward traction of the rectal pouch to confirm its existence, even if radiology is unsuccessful.

Our primary goal for this modification is to separate the rectum from the urinary tract without causing any surgical injury. To achieve this, we utilized the retrovesical space, which is relatively spacious for safe dissection and separation. Pulling the entire circumference of the rectum up creates a distinct boundary between the rectum and the urethra. There are several benefits to this modification. First, it eliminates the need for multiple stay sutures in the rectourethral common wall. Second, it allows the surgeon to see the urinary tract before removing the fistula, which helps them anticipate any risks associated with submucosal dissection. This ultimately reduces the likelihood of injuries. Last, the line of demarcation helps prevent the formation of the posterior urethral diverticulum (PUD).

In a study by Hong and colleagues, a significant number of urologic injuries were associated with PSARP in boys.⁵ The study reported that 3.3% of their patients had suffered from urologic injuries, while 32% of patients referred to them after PSARP had also experienced urological injuries. Major injuries were persistent or recurrent RUF, urethral injury, PUD, and bladder injury. They suspected urethral injuries were due to excess traction on the urethra during the dissection of the rectum. RUF risk factors were not performing a preoperative high-pressure distal loopogram and not placing a urinary catheter before perineal reconstruction. These factors make fistula identification difficult, increasing the risk of rectal or urethral injury and postoperative RUF. PUD occurs mainly in boys with higher fistulas who require an additional abdominal approach, where a portion of the rectum remains attached to the fistula.⁵ None of our patients developed such complications.

Fujiwara and colleagues¹⁰ say lower urinary tract complications are typically linked to certain procedures. Specifically, laparoscopy-assisted anorectoplasty is often connected to PUD, while urinary injuries tend to be associated with PSARP. To avoid urethral injuries, they stressed the importance of visualizing the posterior wall of the urethra.¹⁰ In all patients in this series, we conducted PSARP. Our technique involved mobilizing the rectum first, moving it upwards, and separating it from the retrovesical space. This maneuver allowed us to obtain a better view of the posterior wall of the urethra.

According to Pandey *et al* and Jadhav *et al*, not closing the RUF can decrease the chance of urinary complications as long as the rectum is fully separated from the urethra.^{11 12} Our modified technique guarantees the full

separation of these two tracts and minimizes the risk of any urethral complications.

The patients in our series underwent surgery at a later age than recommended due to delayed arrival, potentially related to their socioeconomic status. Parents had to manage time and money for the procedure. One major drawback of this study is that the follow-up period was relatively short. While most urinary complications resulting from PSARP are detectable immediately, there have been reports of PUD in teenagers and adults.¹³

In conclusion, while technological advancements have occurred, urological injuries in boys are still common during PSARP procedures. However, we firmly believe that urethral injuries can be completely prevented. This requires thorough preoperative preparation and precise visualization of the anatomy during the procedure. Our recommended technique of proximal separation of the urinary tract from the rectum followed by fistula resection can assist pediatric surgeons, particularly those new to the field, in performing PSARP on boys with greater confidence.

Contributors Conceptualization: MSH, AR. Literature review: MSH, UH, RM. Data collection/surgery: MSH, MNI, RM. Manuscript preparation/editing: MSH, UH, MNI. Manuscript review and critical appraisal: AR, MNI, RM.

Funding The authors have not declared a specific grant for this research from any funding agency in the public, commercial or not-for-profit sectors.

Disclaimer The views and opinions expressed in this paper belong to the authors and not the institution.

Competing interests None declared.

Patient consent for publication Consent obtained from parent(s)/guardian(s).

Ethics approval The ethical review committee, Bangladesh Shishu Hospital and Institute. Reference Number: Admin/BSHI/2023/1773, Date 31 July, 2023. Participants gave informed consent to participate in the study before taking part.

Provenance and peer review Not commissioned; externally peer reviewed.

Data availability statement All data relevant to the study are included in the article or uploaded as supplementary information.

Open access This is an open access article distributed in accordance with the Creative Commons Attribution Non Commercial (CC BY-NC 4.0) license, which permits others to distribute, remix, adapt, build upon this work non-commercially, and license their derivative works on different terms, provided the original work is properly cited, appropriate credit is given, any changes made indicated, and the use is non-commercial. See: <http://creativecommons.org/licenses/by-nc/4.0/>.

ORCID iD

Md Samiul Hasan <http://orcid.org/0000-0001-5470-2241>

REFERENCES

- 1 Cassina M, Fascetti Leon F, Ruol M, *et al*. Prevalence and survival of patients with anorectal malformations: a population-based study. *J Pediatr Surg* 2019;54:1998–2003.
- 2 Levitt M, Pena A. Complications after the treatment of Anorectal malformations and redo operations. In: Hohlshneider A, Hustson J, eds. *Anorectal malformations in children: embryology, diagnosis, surgical treatment, follow-up*. Berlin, Heidelberg: Springer, 2007: 319–26.
- 3 Peña A, Hong AR, Midulla P, *et al*. Reoperative surgery for anorectal anomalies. *Semin Pediatr Surg* 2003;12:118–23.
- 4 Tirrell TF, McN

- 6 Peña A, Devries PA. Posterior sagittal anorectoplasty: important technical considerations and new applications. *J Pediatr Surg* 1982;17:796–811.
- 7 Huang Y, Xu W, Xie H, *et al.* Cystoscopic-assisted excision of rectourethral fistulas in males with anorectal malformations. *J Pediatr Surg* 2015;50:1415–7.
- 8 Stenström P, Anderberg M, Kockum CC, *et al.* Endoscopically placed Rectourethral Guidewire facilitates the reconstruction of anus in children with anorectal malformations: a case report. *European J Pediatr Surg Rep* 2013;1:46–7.
- 9 Ming A-X, Li L, Diao M, *et al.* Long term outcomes of laparoscopic-assisted anorectoplasty: a comparison study with posterior sagittal anorectoplasty. *J Pediatr Surg* 2014;49:560–3.
- 10 Fujiwara K, Ochi T, Koga H, *et al.* Lessons learned from lower urinary tract complications of anorectoplasty for imperforate anus with rectourethral/rectovesical fistula: laparoscopy-assisted versus posterior sagittal approaches. *J Pediatr Surg* 2021;56:1136–40.
- 11 Pandey V, Gangopadhyay AN, Gupta DK, *et al.* Management of anorectal malformation without ligation of fistula: an approach preventing posterior urethral diverticula. *J Pediatr Urol* 2014;10:1149–52.
- 12 Jadhav S, Raut A, Mandke J, *et al.* Nonclosure of rectourethral fistula during posterior sagittal anorectoplasty: our experience. *J Indian Assoc Pediatr Surg* 2013;18:5–6.
- 13 Rentea RM, Halleran DR, Vilanova-Sanchez A, *et al.* Diagnosis and management of a remnant of the original fistula (ROOF) in males following surgery for anorectal malformations. *J Pediatr Surg* 2019;54:1988–92.