

Biliary complications post liver resection for pediatric liver tumors

Mohd Yusran Othman ¹, Kok Hoi Teh,² Zakaria Zahari¹

To cite: Othman MY, Teh KH, Zahari Z. Biliary complications post liver resection for pediatric liver tumors. *World J Pediatr Surg* 2023;6:e000589. doi:10.1136/wjps-2023-000589

Received 7 March 2023
Accepted 13 June 2023

ABSTRACT

Objective To review biliary complications following liver resection for liver tumors in children and their associated risk factors.

Methods Retrospectively, we reviewed children who underwent liver resection for liver tumors from 2010 to 2019. Demographic data, operative details, types of complications, interventions and outcomes were studied.

Results Eighty-six out of 108 liver resections were included in this study. The median age of patients was 1.8 years old, and 55% were male. The majority (95%) were malignant tumors, of which 87% were hepatoblastoma (n=71). The most common procedure performed was extended right hepatectomy (37%, n=32). Twelve (14%) patients had primary biliary complications: nine bile leakages and three biliary obstructions. Six cases of bile leakage were treated non-operatively with drainage only; however, one developed bilothorax. Three bile leakages underwent early operative intervention. Four patients underwent biliary reconstruction. Biliary complications were not significantly associated with age, sex, ethnicity or pathology of the tumor. Ten of them (83%) developed following extended hepatectomies (five right, five left), in which the left side had a higher rate of complications (63% vs 16%). None of the central hepatectomies had biliary complications. Biliary complication rates were significantly higher among those who had segmentectomy 1 (p=0.023).

Conclusions Biliary complication is a significant morbidity following liver resection in children. Surgery is eventually required for complicated bile leakage and primary biliary strictures. Follow-up is mandatory since secondary biliary complications may occur after the initial resolution of bile leakage. The groups at high risk of developing biliary complications are extended left hepatectomies and segmentectomy 1.

INTRODUCTION

Complete surgical resection of a malignant liver tumor in children is mandatory for long-term cure. With the advancement of neoadjuvant chemotherapy for hepatoblastoma, a successful resection rate has contributed to a 5-year survival of up to 92%.¹ However, liver resection for pediatric liver tumors is a technically challenging procedure, and Busweiler *et al* reported an overall complication rate of 58%.¹

Biliary complications following liver resection are dreaded complications, specifically bile leakage and biliary stricture. It can occur

WHAT IS ALREADY KNOWN ON THIS TOPIC

⇒ Biliary complications following liver resection and transplantation are known complications; however, the literature on biliary complications following liver resection for childhood liver tumors is scarce.

WHAT THIS STUDY ADDS

⇒ Biliary leakage is the most common complication and can mostly be treated with a non-operative approach.

⇒ Postoperative obstructive jaundice needs to be evaluated for the possibility of biliary stricture.

HOW THIS STUDY MIGHT AFFECT RESEARCH, PRACTICE OR POLICY

⇒ Secondary biliary complications may occur after resolution or intervention of the primary complications; thus, close follow-up is necessary.

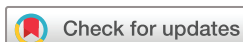in 5%–12.5% of children, and in 1%–7% of adults.² Management strategies for these biliary complications in children are still unclear and potentially delay the initiation of postoperative adjuvant chemotherapy.

The aim of this study is to retrospectively review the biliary complications following liver resection in our center, to identify the risk factors and to study the treatment approaches and outcomes.

METHODOLOGY

This is a retrospective study for a period of 10 years starting from 2010 to 2019. All patients who underwent liver resection for liver tumors in Hospital Tunku Azizah (or previously in Institute of Pediatric, Hospital Kuala Lumpur) during the study period were included. Liver resection for tumor recurrence or completion hepatectomy and patients with incomplete data were excluded.

During this study period, the liver transplantation program was developing gradually in the country. Option for liver transplantation for hepatoblastoma either as primary treatment or as a rescue transplant was not readily available. As the tertiary referral center, resections were attempted in all cases, including extreme resection in PRETEXT



© Author(s) (or their employer(s)) 2023. Re-use permitted under CC BY-NC. No commercial re-use. See rights and permissions. Published by BMJ.

¹Department of Paediatric Surgery, Hospital Tunku Azizah (Kuala Lumpur Women's and Children's Hospital, Ministry of Health Malaysia), Kuala Lumpur, Malaysia

²Department of Paediatrics, Hospital Tunku Azizah (Kuala Lumpur Women's and Children's Hospital, Ministry of Health Malaysia), Kuala Lumpur, Malaysia

Correspondence to

Dr Mohd Yusran Othman;
yusranothman@gmail.com

(PRE-Treatment EXTent of tumor) IV lesions, that is, extended hepatectomies and nodulectomies in the remaining single sector. Almost all resections were performed by a single surgeon (ZZ). Resections were performed using Harmonic scalpel, and ultrasonic dissector was only available since mid-2019. In selected cases following more extensive liver resection, the resection bed was carefully checked for any biliary leakage. We previously performed an intraoperative cholangiogram; however, the yield was unsatisfactory, and images were difficult to be interpreted. Subsequently, we performed saline flushing via the gall bladder, and any obvious leakage was repaired primarily with sutures. Except in one case, hemostatic patch or tissue sealant was not used. Drain insertion was not routine in our practice.

Biliary complications such as bile leakage and biliary stricture that occurred after the surgery were grouped as primary complications, while any biliary-related sequelae following the primary complications were grouped as secondary complications. According to the International Study Group of Liver Surgery, bile leakage is defined as the presence of bilirubin in the abdominal drainage or intraperitoneal fluid or after the third day following surgery or the need for intervention due to bile collection or biliary peritonitis.³ Since measurement of bilirubin is not routine in our center, any gross bile seen in the drainage or the collection was included. Biliary stricture was defined as clinical obstructive jaundice with evidence of proximal biliary dilatations on ultrasound. Cholangiographic assessment by either percutaneous transhepatic cholangiogram (PTC) or endoscopic retrograde cholangiopancreatography (ERCP) was not routinely performed.

The data analysis was performed using SPSS V.22. Descriptive data were described as median with IQR. Mann-Whitney U tests were performed for continuous non-parametric variables. Categorical data were analyzed using χ^2 test or Fisher's exact test. A value of $p < 0.05$ was considered statistically significant.

RESULTS

Throughout the 10-year duration, 108 patients underwent liver resections for liver tumors, of which only 86 patients with adequate data were included. The median age of the studied population was 1.8 years old, with an almost equal distribution between males and females (1.2:1). The ethnic distribution was primarily Malays (64%), followed by Chinese (21%) and Indian (6%), which represents the usual ethnic distribution in Malaysia. Ninety-five per cent of the cases were malignant liver tumors, with hepatoblastoma accounting for 87%. Extended hepatectomies were the most common type of resection performed, and 80% of these were right sided (table 1).

The rate of biliary complications was 14% ($n=12$), which was contributed mainly by bile leakage ($n=9$, 75%). The clinical data of the 12 patients were summarized in table 1; however, some clinical details were not included

Table 1 Demographic and clinicopathological description of the patients who underwent liver resection

Factors	Values (n=86)
Age (years), median (IQR)	1.8 (3.0)
Gender, n (%)	
Male	47 (55%)
Female	39 (45%)
Race, n (%)	
Malay	55 (64%)
Chinese	18 (21%)
Indian	5 (6%)
Others	8 (9%)
Pathology, n (%)	
Malignant tumor (n=82, 95%)	
Hepatoblastoma	71 (83%)
Hepatocellular carcinoma	4 (5%)
Undifferentiated embryonal sarcoma	4 (5%)
Secondary tumors (metastasis)	
Wilms tumor	2 (2%)
Pancreatoblastoma	1 (1%)
Benign tumors (n=4, 5%)	
Hamartoma	3 (3%)
Hemangioma	1 (1%)
Type of liver resection, n (%)	
Extended hepatectomy	40 (46%)
Central hepatectomy	3 (4%)
Hemihepatectomy	27 (31%)
Others	16 (19%)
Side of liver resection, n (%)	
Extended right hepatectomy	32 (37%)
Extended left hepatectomy	8 (9%)
Right hemihepatectomy	18 (21%)
Left hemihepatectomy	9 (10%)
Central hepatectomy	3 (4%)
Others	16 (19%)

IQR, interquartile range.

due to inadequacy of data, especially for the referral cases from other hospitals, such as alpha-fetoprotein level, PRETEXT staging and chemotherapy. All diagnoses of biliary complications were made based on gross inspection of bile in the postoperative drain or seen in the percutaneously inserted drain following detection of postoperative collection on ultrasound. None had a biochemical conformation of measuring bilirubin level within the fluid. The majority (6/9) were successfully managed non-operatively with tube drainage of the bile, and 83% (5/6) resolved without any secondary biliary complications. However, one patient developed bilothorax, which was

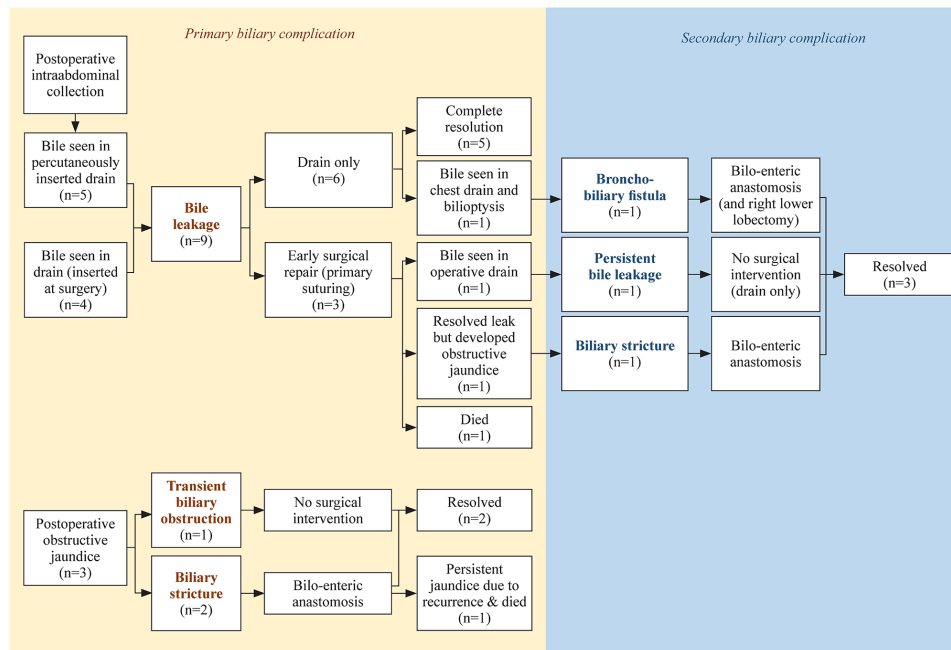


Figure 1 Diagram representing types of biliary complications, management and outcome.

subsequently complicated with bronchobiliary fistula and required right lower lobectomy and biliary reconstruction. Three patients underwent surgical intervention for bile leakage, that is, relaparotomy and primary repair with suturing. One patient died soon after the surgery for sepsis, one developed persistent bile leakage that then resolved after prolonged drainage, and one patient eventually developed secondary biliary stricture that subsequently required biliary reconstruction (figure 1).

Primary biliary stricture was noted in two patients, as evidenced by the development of obstructive jaundice. One patient developed obstructive jaundice within 2 weeks after surgery, with ultrasound findings of dilated intrahepatic ducts. However, this resolved spontaneously without any intervention. Two patients underwent biliary reconstruction; one achieved resolution and another had persistent jaundice along with early tumor recurrence. All of them had different types of hepatic resections (table 2).

There was no significant difference in terms of age, gender distribution, ethnicity and pathology of the tumor in contributing to the development of biliary complications (table 3). Although most of them (74%) received neoadjuvant chemotherapy before surgery, the rate of biliary complications was not significantly higher among them. A total of 83% (10/112) of the biliary complications occurred following an extended type of resection, 5 each from right-sided and left-sided extended hepatectomies. However, the rate of biliary complications was higher in left-sided extended hepatectomies (63%, 5/8) than in right-sided extended hepatectomies (16%, 5/32). None of the central hepatectomies had biliary complications. Fourteen patients had segmentectomy I along with the main resection, and 36% (5/14) of them had biliary complications, which was significantly higher compared

with those who did not undergo segmentectomy I (10%, 7/72) ($p=0.023$). The median operative time was longer in those who had biliary complications than those without biliary complications ($p=0.028$) (table 3).

DISCUSSION

Biliary complications have long been established in children postliver resection and transplantation. These surgeries carry various spectra of biliary issues. Biliary complications following liver transplantation have been well described in the literature, especially issues related to biliary reconstruction, that is, biliary leakage from an anastomotic leak and biliary stricture at the anastomotic site. On the other hand, hepatectomy without biliary reconstruction in tumor surgery carries a risk of biliary leakage from the injured external biliary duct and raw surface of the liver. Only a few studies have described the issues, and the management algorithm is still unclear.

Biliary leakage following liver resection can be divided into either peripheral or central types, according to the findings of ERCP or PTC.⁴ If the leaking bile ducts communicate with the biliary tree, it is defined as central type. If no communication is seen, bile leakage is defined as peripheral type. Unfortunately, our data on cholangiograms were scarce, as it is not a routine practice to perform ERCP or PTC in children with this problem. It is postulated that most of our biliary leakage is peripheral, explaining the resolution with a non-operative approach in approximately 50% of cases.

Diagnosis of biliary leakage can be made in the presence of bile in the inserted drain at surgery or percutaneously inserted drain in those with suspected bile peritonitis. Measurement of bilirubin in the drainage effluent may confirm the diagnosis. Non-operative management

Table 2 Details of patients who developed biliary complications*

No	Age (years)/ Gender	Liver resection		Primary complication		Secondary complication			Outcome
		Type		Type	Presentation	Management	Type	Management	
1	1.8/Male	Extended left		Stricture	Obstructive jaundice with dilated IHD within 2 months PO	Bilio-enteric anastomosis	-	-	Persistent jaundice for early recurrence (died)
2	1.4/Female	Extended right and nodulectomy		Leakage	Intra-abdominal collection at day 7 PO with bile on drainage	Primary suturing at day 20 PO	Persistent leak	Conservative (drain for 55 days)	Resolve
3	3.9/Male	Right hepatectomy and nodulectomy		Stricture	Obstructive jaundice 13 days PO with dilated IHD	Non-operative: resolved within 2 months	-	-	Resolve but had recurrence
4	0.8/Male	Extended left		Leakage	Bile in operative drain	Primary suturing at day 4 PO	-	-	Died at day 10 PO (sepsis)
5	0.8/Male	Extended right		Stricture	Obstructive jaundice within 6 months	Bilio-enteric anastomosis	-	-	Resolved
6	1.8/Male	Left hepatectomy and segmentectomy 8		Leakage	Intra-abdominal collection at day 17 PO with bile on drainage	Non-operative: resolved within 7 days	-	-	Resolved
7	1.5/Male	Extended left		Leakage	Intra-abdominal collection at day 8 PO with bile on drainage	Non-operative: resolved within 2 months	-	-	Resolved
8	6.7/Female	Extended left		Leakage	Bile in operative drain at day 8 PO	Non-operative: resolved within 17 days			Resolved
9	2.7/Female	Extended right		Leakage	Intra-abdominal collection at day 8 PO with bile on drainage	Primary suturing at day 33 PO	Stricture	PTBD then bilio-enteric anastomosis	Resolved
10	11.1/Female	Extended right		Leakage	Intra-abdominal collection at day 5 PO with bile on drainage	Non-operative (at least 4 weeks on drain)	-	-	Resolved
11	0.7/Male	Extended right		Leakage	Bile in operative drain at day 12 PO	Non-operative: resolved within 6 weeks	Bilothorax and bronchobiliary fistula	Bilio-enteric anastomosis	Resolve but had recurrence (died)

Continued

Table 2 Continued

No	Age (years)/ Gender	Liver resection		Primary complication		Secondary complication			Outcome
		Type		Type	Presentation	Management	Type	Management	
12	1.0/Male	Extended left and nodulectomy		Leakage	Intra-abdominal collection at day 13 PO with bile on drainage	Non-operative: resolved within 2 months	-	-	Resolve but had recurrence (died)

*All of them were diagnosed to have hepatoblastoma. IHD, intrahepatic duct; PO, postoperative; PTBD, percutaneous transhepatic biliary drainage.

should be attempted for up to 2 weeks after the surgery by keeping the postoperative drain until no gross bile is seen in the drainage or by inserting a new drain percutaneously. Resolution of bile leakage is expected to occur within a few weeks. A drainage volume of <20 mL/kg/day with a decreasing trend can be clinically observed, and chemotherapy may be resumed even though resolution is longer than expected. Our series showed early resolution as early as 7 days and up to 2 months. However, if a persistent high volume of bile drainage requiring fluid replacement is encountered, surgical intervention should be considered as per the major leak from the central type. Further imaging should be performed to evaluate the possibility of radiological or surgical intervention. Bilio-enteric anastomosis is almost impossible in the absence of dilated ducts. However, primary suturing or diversion with percutaneous transhepatic biliary drainage may allow eventual development of biliary stricture with gradual dilatation of intrahepatic ducts for future bilio-enteric anastomosis.

Three patients in our series underwent early surgery for biliary leakage. None of them underwent biliary reconstruction as the primary intervention because the leakage site was usually small, and primary suturing was attempted. One patient died soon after surgery from severe sepsis, and the other two developed secondary biliary complications. One patient had persistent biliary leakage that subsequently resolved spontaneously, and the other patient developed biliary stricture and underwent bilio-enteric anastomosis. Both of them achieved resolution of the biliary issue.

A spontaneously healed bile leakage needs to be followed up for any secondary complications, namely, formation of chronic biloma and development of biliary fistula. Chronic biloma with biliocutaneous fistula has been reported in a case of resection for hepatoblastoma, but none were observed in our series.⁵ Biliothorax and bronchobiliary fistula are other rarer complications, as seen in one of our patients. The symptoms were initially ascribed to pneumonia with right pleural effusion. Drainage was needed for the effusion since he required more intensive ventilatory support, and the drainage was found to be bilious in content. Again, the non-operative approach seemed to work well when he was discharged home well after chest drainage. However, recurrence of symptoms with biliptysis has been the hallmark for the development of bronchobiliary fistula. This compromised his ventilation, and persistent bilious secretion continued to flood the endotracheal tube. An emergency right thoracotomy was performed, and right lower lobectomy with fistula repair at the diaphragm was performed, followed by a delayed bilio-enteric anastomosis 5 days later. Various mechanisms have been described as causes of biliothorax or bronchobiliary fistula. The presence of a direct passage in the diaphragm may allow the bile to traverse through, and it may occur following trauma, erosive defects or even congenital defects.⁶ Indirect passage through the connective tissue sheath of the esophagus and the great

Table 3 Analysis of the factors associated with postoperative biliary complications

Factors	No biliary complications (n=74)	Biliary complications (n=12)	χ^2 statistic* (df)	P value
Age (years), median (IQR)	1.8 (3.0)	1.6 (2.8)	–	0.980†
Gender, n (%)				
Male	39 (53%)	8 (67%)		
Female	35 (47%)	4 (33%)	0.81 (1)	0.367*
Race, n (%)				
Malay	49 (66%)	6 (50%)		
Non-Malay	25 (34%)	6 (50%)	–	0.337‡
Pathology, n (%)				
Hepatoblastoma	59 (80%)	12 (100%)		
Non-hepatoblastoma	15 (20%)	0 (0%)	–	0.115‡
Neoadjuvant chemotherapy§, n (%)				
Yes	52 (72%)	9 (82%)		
No	20 (28%)	2 (17%)	–	0.719‡
Type of resection, n (%)				
Extended hepatectomy	30 (41%)	10 (83%)		
Non-extended	44 (59%)	2 (17%)	7.60 (1)	0.006*
Segmentectomy 1, n (%)				
Yes	9 (12%)	5 (42%)		
No	65 (88%)	7 (58%)	–	0.023‡
Operative time (min), median (IQR)	210 (96)	287 (121)	–	0.028†

* χ^2 test for independence.
†Mann-Whitney U test.
‡Fisher's exact test.
§Unknown in three patients.
IQR, interquartile range.

vessels may also allow bile to enter into the mediastinum.⁶ In our case, no diaphragmatic defect was encountered during the surgery. Knowing the corrosive effect of the bile, we postulated that the diaphragmatic fistula developed following the inflammatory reaction of leaked bile from the hepatic resection.^{6,7} Bile collection induces an inflammatory reaction in the subdiaphragmatic area, causing spontaneous rupture into the thoracic cavity and subsequently creating a connection into the bronchial system.⁸

Another major biliary issue after liver resection is biliary stricture. Primary biliary stricture can be diagnosed following an episode of obstructive jaundice with evidence of intrahepatic duct dilatation. If symptoms persist or obstructive jaundice appears later than 2 weeks after surgery, surgical intervention should be anticipated.

The literature on non-anastomotic biliary stricture (NAS) in children was mainly discussed in relation to liver transplantation, which described that NAS may occur secondary to hepatic artery thrombosis, ischemia secondary to microangiopathic injury (such as prolonged ischemia times), or secondary to immunogenetic injury (such as rejection).⁹ In relation to stricture after hepatectomy, ischemia of the bile ducts may occur following

vascular insult during dissection, which may result in partial or complete biliary necrosis. Stricture is expected to present with features of cholestatic jaundice, and proximal duct dilatation is a pertinent feature to enable future biliary drainage via surgery.

We encountered one case of early development of cholestatic jaundice within 2 weeks after surgery with evidence of intrahepatic duct dilatation, and resolution was achieved without the need for any surgical intervention. Postulation made was either due to resolution of edema at the surgical field or development of collaterals that allowed recovery of the biliary necrosis. Another two patients with stricture had bilio-enteric anastomosis in which one achieved resolution and another had persistent jaundice following early recurrence compounded by the background issue of cyanotic heart disease.

Risk factors for biliary leakage have been well described in the adult literature. From a systematic review on adult series on hepatectomy without biliary reconstruction, sex, diabetes, extended left hepatectomy, central hepatectomy, segmentectomy 1, intraoperative blood transfusion and intraoperative bleeding 1000 mL were identified as risk factors for biliary leakage.³ Limited data have been reported regarding risk factors for bile leakage in

children. Steen *et al* found overall biliary complications to be higher in younger age groups, suggesting that age is one of the possible risk factors.² Compared with adults who primarily undergo hepatectomy for metastases, children usually undergo liver resection for the primary tumor after receiving neoadjuvant chemotherapy, which may contribute to complications. However, Steen *et al* commented that this statement was contradictory to the findings that most of the biliary complications in their series were seen in those with benign disorders and did not receive chemotherapy (four out of seven cases).² The results of a report by Busweiler *et al* also do not support the hypothesis of neoadjuvant chemotherapy as one of the risk factors since all children in their series received neoadjuvant chemotherapy and the overall complication rates were relatively low. In fact, they emphasized the role of neoadjuvant chemotherapy in downstaging the tumor and resulting in less extensive liver resection.¹ They suggested further investigation of the operative technique and surgeon experience as risk factors for biliary complications. In our series, we grouped both biliary leakage and stricture as the biliary complication group. Age, sex, ethnicity and pathology were not significantly different in both groups, and since almost all our surgeries were performed by a single surgeon, technical factors would be difficult to comment on objectively. The rate of biliary complications was also not significantly higher in children who received neoadjuvant chemotherapy. Extended hepatectomies were found to be a significant risk factor. Although equal numbers of left and right extended hepatectomies were recorded in our series, it is noteworthy that the relative rate of biliary complications after extended left hepatectomy was higher than that after right hepatectomy (63% vs 16%). In addition, segmentectomy 1 was found to have a significantly higher risk of developing biliary complications. None of our central hepatectomies developed biliary complications. The timing of surgery was significantly longer in those who had biliary complications, which explains the complexity or extensive surgery, as extended hepatectomies and segmentectomy 1 require longer surgeries and thus are associated with more complications.

The limitation of this study is that it is retrospective. A few cases in earlier years had incomplete records for inclusion in the study, and many of them were followed up in the primary referral centers. Few biliary leakages were sent back to the referral center after hepatectomy, and thus, we were unable to determine the exact timing of resolution following a non-operative approach in some of the cases. With the assumption of no referral made to our center for any complex biliary complications, we assumed that the excluded cases were those without biliary complications and that the overall complication rate was presumed to be even <14%. It is noteworthy that tumor recurrence seems to be high among this cohort of patients. It is postulated that this group of children would benefit from a decision on primary transplant instead of extensive liver resection. Another limitation is that the

diagnosis of biliary leakage was made solely based on visual identification rather than objective measurement of bilirubin in the fluid; thus, the true incidence may be underestimated.

In conclusion, biliary complication is a significant morbidity following liver resection in children, with biliary leakage being the most common complication that can be treated non-operatively. Any postoperative obstructive jaundice needs to be evaluated for biliary stricture and may need surgical intervention. Secondary biliary complications may occur after resolution or intervention for primary complications, mandating close follow-up. Extended hepatectomies, especially left-sided hepatectomies, and those needing segmentectomy 1 are at high risk of developing biliary complications.

Acknowledgements We would like to thank the Director General of Health Malaysia for his permission to publish this article.

Contributors MYO: guarantor, conceptualization, data curation, formal analysis, investigation, methodology, project administration, resources, visualization, writing—original draft. KHT and ZZ: conceptualization, methodology, supervision, validation, writing—review and editing.

Funding The authors have not declared a specific grant for this research from any funding agency in the public, commercial or not-for-profit sectors.

Competing interests None declared.

Patient consent for publication Not applicable.

Ethics approval This study was approved by the Medical Research and Ethics Committee (MREC), Ministry of Health Malaysia (MOH) (NMRR-19-4070-50648 (IIR)).

Provenance and peer review Not commissioned; externally peer reviewed.

Data availability statement Data are available on reasonable request.

Open access This is an open access article distributed in accordance with the Creative Commons Attribution Non Commercial (CC BY-NC 4.0) license, which permits others to distribute, remix, adapt, build upon this work non-commercially, and license their derivative works on different terms, provided the original work is properly cited, appropriate credit is given, any changes made indicated, and the use is non-commercial. See: <http://creativecommons.org/licenses/by-nc/4.0/>.

ORCID iD

Mohd Yusran Othman <http://orcid.org/0000-0001-7673-9029>

REFERENCES

- 1 Busweiler LAD, Wijnen MHWA, Wilde JCH, *et al*. Surgical treatment of childhood hepatoblastoma in the Netherlands (1990 – 2013). *Pediatr Surg Int* 2017;33:23–31.
- 2 Steen MW, Bakx R, Tabbers MM, *et al*. Endoscopic management of biliary complications after partial liver resection in children. *J Pediatr Surg* 2013;48:418–24.
- 3 Tan L, Liu F, Liu ZL, *et al*. Meta-analysis of risk factors for bile leakage after hepatectomy without biliary reconstruction. *Front Surg* 2021;7:64211.
- 4 Sakamoto K, Tamesa T, Yukio T, *et al*. Risk factors and managements of bile leakage after hepatectomy. *World J Surg* 2016;40:182–9.
- 5 Murphy AJ, Rauth TP, Lovvorn HN. Chronic biloma after right hepatectomy for stage IV hepatoblastoma managed with Roux-en-Y biliary Cystenterostomy. *J Pediatr Surg* 2012;47:e5–9.
- 6 Hamers LAC, Bosscha K, van Leuken MH, *et al*. Biliothorax: a bitter complication of liver surgery. *Case Rep Surg* 2013;2013:372827.
- 7 Singh B, Moodley J, Sheikh-Gafoor MH, *et al*. Conservative management of thoracobiliary fistula. *Ann Thorac Surg* 2002;73:1088–91.
- 8 Chua HK, Allen MS, Deschamps C, *et al*. Bronchobiliary fistula: principles of management. *Ann Thorac Surg* 2000;70:1392–4.
- 9 Feier FH, da Fonseca EA, Seda-Neto J, *et al*. Biliary complications after pediatric liver transplantation: risk factors, diagnosis and management. *World J Hepatol* 2015;7:2162–70.