

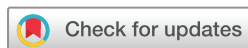Epigastric hernias in children and the use of ultrasound in its diagnosis

Tatjana T König,¹ Laura S Oerters,² Ljuba Spiller,³ Martin Schwind,¹ Mark Born,³ Christina Oetzmann von Sochaczewski ^{1,2}, Andreas C Heydweiller²

To cite: König TT, Oerters LS, Spiller L, et al. Epigastric hernias in children and the use of ultrasound in its diagnosis. *World Jnl Ped Surgery* 2023;6:e000544. doi:10.1136/wjps-2022-000544

Excerpts of the present study have been presented at the 7th WOFAPS Conference in Prague in October 2022.

Received 7 December 2022
Accepted 16 March 2023



© Author(s) (or their employer(s)) 2023. Re-use permitted under CC BY-NC. No commercial re-use. See rights and permissions. Published by BMJ.

¹Klinik und Poliklinik für Kinderchirurgie, Universitätsmedizin der Johannes Gutenberg-Universität Mainz, Mainz, Germany

²Sektion Kinderchirurgie der Klinik und Poliklinik für Allgemein-, Viszeral-, Thorax- und Gefäßchirurgie, Universitätsklinikum Bonn, Bonn, Germany

³Sektion Kinderradiologie der Klinik für Diagnostische und Interventionelle Radiologie, Universitätsklinikum Bonn, Bonn, Germany

Correspondence to

Christina Oetzmann von Sochaczewski; c.oetzmann@gmail.com

ABSTRACT

Introduction There is a paucity of clinical data on pediatric epigastric hernias despite them accounting for up to 6% of all hernia repairs in children. We aimed to provide additional data to supplement those 117 cases of a recent systematic review and to further clarify the role of ultrasound in diagnosing pediatric epigastric hernia.

Methods We retrospectively included all 60 patients treated for epigastric hernias in children in two tertiary pediatric surgical departments within 12 years.

Associations were tested via point-biserial correlation analyses.

Results Epigastric hernias primarily affected preschool children with a median age of 39 months. The vast majority of patients (88%) presented with swelling that was occasionally (30%) accompanied by pain. Fascial defects could be found during clinical examination in 45% of patients with a median size of 5 mm (95% CI 3 to 10). Smaller defects were less likely to be palpable ($r=-0.44$, 95% CI -0.08 to -0.7 , $p=0.021$). Likewise, ultrasound was used more frequently with smaller fascial defect sizes ($r=-0.51$, 95% CI -0.16 to -0.74 , $p=0.007$). Laparoscopic repair was used in 11 patients (19%) and more often (4/11) in combination with another simultaneous procedure than open repair (11/48).

Conclusions Epigastric hernias are primarily a condition of the preschool child. Ultrasound can be beneficial if the diagnosis cannot be made clinically; otherwise, it is abdicable if it does not change the management of the patient's epigastric hernia. Laparoscopic repairs might be beneficial for children with multiple defects or simultaneous procedures.

INTRODUCTION

Ventral hernias, among which epigastric hernias are the most frequent, accounted for 6% of all pediatric hernia repairs in an analysis of the Military Health System Data Repository of the USA.¹ Likewise, 4% of all hernia repairs in a relatively large retrospective analysis were epigastric hernias.² Despite these numbers, a recent systematic review identified clinical information on only 81 pediatric patients in the literature.³ Together with their simultaneously reported 36 patients,³ there is clinical information from just 117 patients, which we consider a relevant paucity of data. We aimed to address this by providing

WHAT IS ALREADY KNOWN ON THIS TOPIC

⇒ Epigastric hernias are relatively frequent in children, but clinical data are scarce, with only 117 cases described in the literature thus far.

WHAT THIS STUDY ADDS

⇒ Patients might benefit from an ultrasound examination if their epigastric hernia cannot be diagnosed clinically or not localized preoperatively.

HOW THIS STUDY MIGHT AFFECT RESEARCH, PRACTICE OR POLICY

⇒ Ultrasound for epigastric hernia should be reserved for equivocal cases in which it alters the management and is ordered by the treating pediatric surgeon.

additional clinical information on this condition with relevant case numbers. Despite these limited data, there is a debate regarding whether ultrasound would be helpful to diagnose the condition⁴ or not.³ As ultrasound is frequently used in one of our centers, we also aimed to further address this issue.

PATIENTS AND METHODS

We retrospectively included all patients below 18 years of age diagnosed with epigastric hernias in the two participating tertiary pediatric surgical departments from 1 January 2009 to 31 December 2020. The available data were screened for misclassified umbilical or incisional hernias, but none were identified. Patients were identified via the specific diagnosis codes according to the International Statistical Classification of Diseases and Health Related Problems in the German Modification for an epigastric hernia (K43.60/K43.70/K43.90). Data extraction with anonymization at the source was carried out by specifically trained chart abstractors using a prespecified data extraction chart, which was occasionally cross-checked to ensure the quality of extracted data as recommended elsewhere.⁵ We collected information on age, sex, body weight and height,

symptoms on presentation, clinical findings, defect size, the preoperative use of ultrasound for diagnosis, and operation times. As there are no clear distinctions in the literature of what accounts for a periumbilical, supraumbilical and an epigastric hernia,⁶ we used the following definitions: periumbilical hernias were those immediately adjacent to the umbilical ring but were excluded from the analysis because they frequently occur in association with umbilical hernias. Supraumbilical hernias^{7,8} were those epigastric hernias that were located up to 3 cm rostral to the umbilicus because anatomical studies have shown that the linea alba may have different properties there compared with more rostral parts^{9,10} and are clinically thought to be different from umbilical hernias.^{11,12} All more rostrally located epigastric hernias were considered true epigastric hernias. Ultrasound examinations were ordered at the discretion of the treating surgeon in both centers. All ultrasound examinations of epigastric hernias were conducted by board-certified pediatric radiologists in a standardized fashion. Open repairs, illustrated elsewhere,⁸ were usually performed via a transverse incision, in some cases with larger hernias via a longitudinal incision, located directly above the preoperatively marked hernia. Subcutaneous tissue was transected using electrocautery until the hernia was reached and exposed circumferentially. Following manual reduction of the hernia or if it was unsuccessful, the herniated fat was ligated and divided, and the fascia was closed using simple interrupted sutures. Available fascial defect sizes were measured intraoperatively and taken from the operation notes. The laparoscopic approach used in this report has been described in detail elsewhere.¹³ Statistical analysis was conducted using R¹⁴ (V.3.5.3) with its generic stats4 package. Differences in medians of numeric variables were compared via Mood's test, and correlation analyses used point-biserial correlation from the correlation package¹⁵ (V.0.8.0).¹⁶ The normality of the data was checked via the Jarque-Bera test from the tseries package (V.0.10-52)¹⁷ supported by visual analysis of QQ plots. Homogeneity of variance between groups was tested via Levene's test using the car package (V.3.0-7).¹⁸ Symptoms and results of the clinical examination, as dichotomous variables, were compared between males and females using Barnard's test¹⁹ provided in the Barnard package²⁰ (V.1.8) as described elsewhere.^{21,22} In the jurisdiction of our ethics committees, retrospective analyses of routine

clinical data with anonymization at the source are waived from institutional review board approval.

RESULTS

We included 60 patients, of which 28 were females, resulting in an almost even sex ratio of 1:1.14. The median age of patients was 39 months (IQR 24–77 months). There were no differences between sexes in terms of age and body mass index (table 1).

One patient had two epigastric hernias, and another even had three epigastric hernias at different positions of the midline. Three (5%) patients had a coexisting inguinal hernia, and four (7%) had a coexisting umbilical hernia. An incisional hernia following a laparoscopic appendectomy was present in another patient. The leading symptom on presentation was pain in 18 (30%) patients, which occurred conjointly with swelling in 15 of them, while the remaining three patients had pain without visible swelling. Swelling was present in 53 (88%) patients during clinical examination, resulting in four (7%) patients who had a history of swelling that vanished spontaneously and could not be reproduced by maneuvers to increase the intra-abdominal pressure. A fascial defect was palpable in 27 (45%) patients. There was no difference in the distribution of symptoms between sexes (table 1).

Of those patients in whom the patient records were detailed enough to assess this aspect, 25 (42%) hernias could be classified as supraumbilical and 28 (47%) as truly epigastric, while it remained unclear in seven patients. Lateralization of the hernias could be assessed in 36 patients, in whom 30 hernias were localized in the midline, while three were left (two supraumbilical) and three epigastric hernias right of it. In the remaining 24 patients, the recorded information was not detailed enough to clearly answer this question. Fascial defects had a median size of 5 mm (95% CI 3–10). Supraumbilical hernias had numerically larger fascial defects with a median of 10 mm (95% CI 2 to 15, n=7) compared with epigastric hernias with a median of 3 mm (95% CI 2 to 9, n=17), but this was not the case statistically ($z=0.289$, $p=0.773$). As expected, smaller fascial defects were less likely to be found during clinical examination ($r=-0.44$, 95% CI -0.08 to -0.7 , $p=0.021$, $n=27$). Consequently, those patients with a smaller fascial defect size (figure 1A)

Table 1 Demographic details of the included patients

| Variables | Whole cohort N=60 | Females n=28 | Males n=32 | P value |
|---|----------------------|------------------|------------------|---------|
| Age in months, median (IQR) | 39 (24–77) | 26.5 (17–53) | 51 (28–101) | 0.266 |
| Body mass index in kg/m ² , median (IQR) | 16.6 (15.2–18) | 16.9 (14.3–17.3) | 16.6 (15.5–18.4) | 0.556 |
| Pain, n (%) | 18 (30) | 7 (25) | 11 (34) | 0.530 |
| Swelling, n (%) | 53 (88) | 24 (86) | 29 (91) | 0.621 |
| Palpable fascial defect, n (%) | 27 (45) | 14 (50) | 13 (41) | 0.530 |

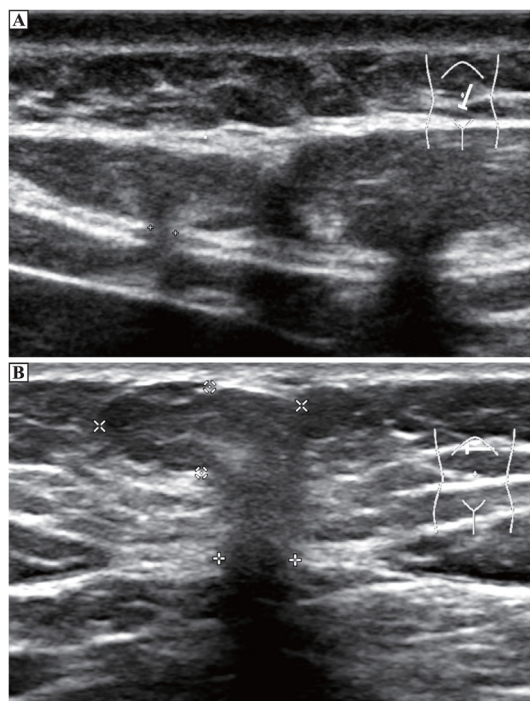


Figure 1 Comparative ultrasound images of epigastric hernias with small and large defect sizes. (A) Small fascial defect. (B) Large fascial defect with visibly herniated pre-peritoneal fat inside the hernia sac. The symbols in both panels denote size measurements of the fascial defects and the hernia sac in B.

were more likely to have had an ultrasound to establish the diagnosis ($r=-0.51$, 95% CI -0.16 to -0.74 , $p=0.007$, $n=27$) (table 2) compared with those with a larger fascial defect size (figure 1B). Ultrasound was used in 16 patients and confirmed the diagnosis of an epigastric hernia in all of them by visualizing a fascial defect.

Of the 60 patients, 59 received operative defect closure, which was performed laparoscopically in 11 (19%) patients, while the remaining patients were treated with open repair. The laparoscopic approach (median 52 min, 95% CI 25 to 100) was only numerically associated with a longer median operation time ($z=1.815$, $p=0.07$) compared with the open procedure (median 30 min, 95% CI 27 to 37). Parallel procedures influencing the operation times were common: 36% (4/11) of laparoscopically operated children had at least one parallel procedure, and 23% (11/48) of open repairs had at least one parallel procedure. Complications following the procedure were rare and occurred in only two patients,

one of whom experienced a postoperative hematoma and the other of whom had persistent localized pain following the operation.

DISCUSSION

Although epigastric hernias in children are common,^{23 23} they are only mentioned incidentally in seminal works²⁴ and textbooks of pediatric surgery,^{25 26} while there is an official clinical guideline for the adult population.⁶ For children with epigastric hernias, there are only limited clinical data available from cohorts with small sample sizes. A recent systematic review identified only 81 children since the 1960s,³ which is surprising for a condition that accounts for 4%–6% of all pediatric hernia repairs.¹²

As in the systematic review,³ preschool children were the common age group for pediatric epigastric hernia in our cohort, although others noted another peak in infants^{1 2} or older children,²³ which might represent a different preference for the timing of surgery.³ Similar to preceding reports,^{2 3} the majority of children in our series presented with asymptomatic swelling, while localized pain was the major complaint in 30% of the included patients. This finding corroborates previous reports with 38%² and 31%³ of patients experiencing localized pain. As reported before,^{2 3} the majority of cases occurred in the midline of the abdomen, whereas paramedian epigastric hernias were rare. Preceding research reported the fascial defects to be small with a median of 3 mm³ and a mean of 7 mm,² while we found a median fascial defect size of 5 mm that was even larger in supraumbilical hernias with a median of 10 mm. Larger defect sizes of up to 25 mm have been described,² and we noticed a maximum defect size of 20 mm in our series in a 2-year-old girl. In our series, nine patients had fascial defects of 10 mm or more.

At the opposite site of the spectrum, there are those patients with small fascial defects: due to the difficulty of palpating them, it has been advised to regularly mark the site of the hernia preoperatively, as it may be difficult to identify it in the supine and relaxed patient.^{2 3} We have been able to establish this association using correlation analyses and indeed found that small fascial defects are much less likely to be found during clinical examination. The palpable fascial defect is not a prerequisite to make the diagnosis: the diagnosis is mainly established by the presence of a (para)median swelling in physical examination.^{3 27} The aspect of the palpable fascial defect is

Table 2 Clinical information separated by the use of ultrasound

| | Fascial defect size | Palpable fascial defect (%) | Supraumbilical hernias (%) | Swelling (%) | Pain (%) | Open repair (%) |
|----------------------|----------------------------|-----------------------------|----------------------------|--------------|----------|-----------------|
| Ultrasound (n=16) | 5 mm (IQR 1–7, n=13) | 3 (19) | 3 (19) | 13 (81) | 6 (38) | 13 (81) |
| No ultrasound (n=44) | 7.5 mm (IQR 3.25–10, n=14) | 24 (55) | 22 (48) | 40 (91) | 12 (27) | 35 (80) |

relevant because the swelling will often disappear in the operating room, but this can be addressed by preoperative marking of the localization of the swelling before induction of anesthesia.^{2,3} Consequently, the use of ultrasound in pediatric epigastric hernia has been debated: some considered it to be exceptional, as the clinical examination will almost always establish the diagnosis,³ while others assumed ultrasound to be useful to establish the diagnosis because in the majority of cases, the fascial defect was not detected without ultrasound.⁴ Ultrasound has been a valuable tool in the evaluation of abdominal wall hernias for decades,²⁸ and due to its high sensitivity and specificity, it may be advantageous when the clinical examination is equivocal.²⁹ The most relevant among these is the differentiation between umbilical hernias and supraumbilical hernias⁷: ideally, epigastric hernia could easily be discerned from umbilical hernias due to a distance to the navel as exemplified by Tinawi and Stringer³ or due to a characteristic U shape of the umbilicus being pushed downward by the epigastric hernia as shown by Shastri and Gilmer.³⁰ If the clinical examination alone could not allow differentiation between these two types of hernia, ultrasound would most likely do so. This differentiation in equivocal cases is also of clinical relevance, as the management differs: while epigastric hernias are usually scheduled for elective repair once diagnosed,^{2,3} watchful waiting for spontaneous closure for asymptomatic umbilical hernia until the age of 4 years has been recommended by a systematic review.³¹ In addition, in umbilical hernias, the defect size is associated with the odds of spontaneous closure, with larger defects being less likely to close spontaneously,³² so the information gained by ultrasound could even be of relevance for counseling the patient's family if an umbilical and not an epigastric hernia is diagnosed. However, ultrasound should not be part of the routine care for epigastric hernia, as it is recommended to refer patients to secondary pediatric surgical care anyway if an epigastric hernia is suspected.³³

In our series, four (7%) patients presented only with a history of swelling but neither a palpable fascial defect nor reproducible swelling in the clinical examination. There might be a role for parental photographs to confirm the presence of an epigastric hernia, either as a virtual diagnosis³⁴ or if a mass is not palpated on clinical examination. Ultrasound may play a limited role in preoperative localization in cases where a mass cannot be palpated. In this case, ultrasound would reliably identify the fascial defect and thus enable the preoperative marking of the level of the fascial defect. One may also argue that these children might rather be observed until the hernia becomes apparent, but one of the affected children in our series was symptomatic with abdominal pain, so observation would not have been indicated, as is commonly described in seminal works.²⁴ Moreover, it has been described that fascial defects in children tend to enlarge during observation or become symptomatic,² but additional data on the natural progress of epigastric

hernias are missing in children.³ In addition, many kids will find rubbing of the hernias against their clothes irritating.^{2,33} In addition to these aspects, it must be taken into account that epigastric hernias might have a relevant risk of non-elective repair, which would be accompanied by an increased anesthetic risk. As the literature and subsequently the opinions of pediatric surgical departments assessed by Tinawi and Stringer³ are divided on the point of whether asymptomatic epigastric hernias should be repaired, some recommend it,^{2,4,7,33} while others prefer watchful waiting,^{13,27} we counsel the parents on both treatment options, but usually, in our experience, the parents will opt for the operative repair.

Although our study is the first to include both laparoscopic and open epigastric hernia repairs, it cannot be seen as a comparative study. A relevant portion of the laparoscopic hernia repairs were conducted in patients with specific circumstances, such as multiple epigastric hernias, concomitant repair of an incisional hernia or other simultaneous operations. Therefore, the number of comparable cases is just too small to derive a reliable result in the comparison of both techniques. Nevertheless, having both techniques within one cohort indicates that laparoscopy might indeed be beneficial if there are multiple defects⁷ or concomitant procedures to be undertaken, while we generally favored the open approach if a single epigastric hernia was to be repaired.

In addition to the retrospective nature of our study, a further limitation is that we cannot provide the direly needed³ long-term data on the spontaneous course of an epigastric hernia and the risk of recurrence following epigastric hernia repair, particularly in children with larger fascial defect sizes. Another limitation of our study is a portion of missing clinical data in several patients, which is common in all reports of pediatric epigastric hernias^{2,3} and thus not specifically caused by poor documentation in our centers. Administrative data might be helpful in covering these issues, although the currently available reports did not assess recurrences¹ or did explicitly exclude them by their study design.²³ Another limitation is that the use of ultrasound was different between the two study centers, which is likely to have introduced additional bias besides the one that is caused by the treating pediatric surgeon deciding whether an ultrasound should be conducted or not.

To date, our study represents the largest cohort of epigastric hernias in children, increasing the available information in the literature by more than 50%. In addition, due to the routine use of ultrasound in one of the two study sites and infrequently in the other study site, our study was able to provide further insight into the role of ultrasound in pediatric epigastric hernias. Its use might be beneficial in patients in whom an epigastric hernia cannot be diagnosed clinically or if a preoperative marking of the level of the hernia was impossible, as preceding research demonstrated that point-of-care ultrasound in the operating room will reliably detect the fascial defect.³⁵ However, outside this limited range

of indications, ultrasound for pediatric epigastric hernia is not a necessity for diagnosis or management and would put an undue burden on radiology departments if ordered routinely.³⁵ Consequently, the treating pediatric surgeon, who will see the child because a referral to secondary care is recommended,³³ should decide whether an ultrasound examination of an epigastric hernia is necessary.

Contributors TTK, CÖvS, and ACH contributed to study conceptualization, study design, acquisition of data, data analysis and data interpretation, and wrote the manuscript. LSO contributed to study conceptualization, study design, acquisition of data, data analysis and data interpretation, and commented critically on the manuscript. LS, MS, and MB contributed to data acquisition, data analysis, and data interpretation, and commented critically on the manuscript. CÖvS is the guarantor of the work. All authors gave final approval of the manuscript.

Funding The authors have not declared a specific grant for this research from any funding agency in the public, commercial or not-for-profit sectors.

Competing interests None declared.

Patient consent for publication Not applicable.

Ethics approval In the jurisdiction of the authors, IRB approval is not necessary for retrospective studies with anonymization at the source

Provenance and peer review Not commissioned; externally peer reviewed.

Data availability statement Data are available upon reasonable request. Deidentified data will be supplied upon request to the corresponding author.

Open access This is an open access article distributed in accordance with the Creative Commons Attribution Non Commercial (CC BY-NC 4.0) license, which permits others to distribute, remix, adapt, build upon this work non-commercially, and license their derivative works on different terms, provided the original work is properly cited, appropriate credit is given, any changes made indicated, and the use is non-commercial. See: <http://creativecommons.org/licenses/by-nc/4.0/>.

ORCID iD

Christina Oetzmann von Sochaczewski <http://orcid.org/0000-0002-3469-777X>

REFERENCES

- 1 Wolf LL, Sonderman KA, Kwon NK, et al. Epidemiology of abdominal wall and groin hernia repairs in children. *Pediatr Surg Int* 2021;37:587–95.
- 2 Coats RD, Helikson MA, Burd RS. Presentation and management of epigastric hernias in children. *J Pediatr Surg* 2000;35:1754–6.
- 3 Tinawi GK, Stringer MD. Epigastric hernias in children: a personal series and systematic review of the literature. *Eur J Pediatr Surg* 2022;32:139–45.
- 4 Jun Z, Na J, Zhen C, et al. Single-Incision laparoscopic approach for linea alba hernia in children. *J Minim Access Surg* 2019;15:42–5.
- 5 Vassar M, Holzmann M. The retrospective chart review: important methodological considerations. *J Educ Eval Health Prof* 2013;10:12.
- 6 Henriksen NA, Montgomery A, Kaufmann R, et al. Guidelines for treatment of umbilical and epigastric hernias from the European hernia Society and Americas hernia Society. *Br J Surg* 2020;107:171–90.
- 7 Brandt ML. Pediatric hernias. *Surg Clin North Am* 2008;88:27–43.
- 8 Carachi R, Agarwala S, Bradnock TJ, eds. *Basic techniques in pediatric surgery*. Berlin, Heidelberg: Springer, 2013.
- 9 Rath AM, Attali P, Dumas JL, et al. The abdominal linea alba: an anatomic-radiologic and biomechanical study. *Surg Radiol Anat* 1996;18:281–8.
- 10 Kaufmann RL, Reiner CS, Dietz UA, et al. Normal width of the linea alba, prevalence, and risk factors for diastasis recti abdominis in adults, a cross-sectional study. *Hernia* 2022;26:609–18.
- 11 Spencer Netto FAC, Mainprize M, Galant G, et al. The incidence of occult paraumbilical hernias in patients undergoing primary umbilical hernia repair. *Hernia* 2021;25:619–23.
- 12 Kuck L, Seitz F, Wiegering A, et al. Ohne Netz und doppelten Boden: Vergleich der Nabelherniotomie nach Spitzzy im Kindes- und Erwachsenenalter. *Zentralbl Chir* 2019;144:32–7.
- 13 Babsail AA, Abelson JS, Liska D, et al. Single-Incision pediatric endoscopic epigastric hernia repair. *Hernia* 2014;18:357–60.
- 14 R Core Team. R: A language and environment for statistical computing. Available: 2019.<https://www.R-project.org> [Accessed 25 Feb 2019].
- 15 Makowski D, Wiernik BM, Patil I, et al. Correlation: methods for correlation analysis. Available: 2022.<https://CRAN.R-project.org/package=correlation> [Accessed 10 Jul 2022].
- 16 Makowski D, Ben-Shachar M, Patil I, et al. Methods and algorithms for correlation analysis in R. *JOSS* 2020;5:2306.
- 17 Trapletti A, Hornik K. tseries: time series analysis and computational finance. Available: <https://CRAN.R-project.org/package=tseries> [Accessed 10 Jan 2023].
- 18 Fox J, Weisberg S, Price B, et al. Car: companion to applied regression. 2018. Available: <https://CRAN.R-project.org/package=car> [Accessed 11 Mar 2020].
- 19 BARNARD GA. Significance tests for 2 X 2 tables. *Biometrika* 1947;34:123–38.
- 20 Erguler K. Barnard: barnard's unconditional test. Available: 2016. <https://CRAN.R-project.org/package=Barnard> [Accessed 14 Jul 2022].
- 21 Oetzmann von Sochaczewski C, Pintelon I, Brouns I, et al. Experimentally induced biliary atresia by means of rotavirus-infection is directly linked to severe damage of the microvasculature in the extrahepatic bile duct. *Anat Rec (Hoboken)* 2019;302:818–24.
- 22 Welk A, Herrnberger M, Engel V, et al. Antimicrobial chemotherapy has a linear relationship to the proportion of gram-negative isolates from pediatric burn wounds. *Klin Padiatr* 2018;230:39–43.
- 23 Burchard J, Pedersen MS, Pommergaard H-C, et al. The prevalence of umbilical and epigastric hernia repair: a nationwide epidemiologic study. *Hernia* 2015;19:815–9.
- 24 Kelly KB, Ponsky TA. Pediatric abdominal wall defects. *Surg Clin North Am* 2013;93:1255–67.
- 25 Sinha CK, Davenport M, eds. *Handbook of pediatric surgery*. Second Edition. Cham: Springer International Publishing, 2022.
- 26 Mattei P, Nichol PF, Rollins, II MD, eds. *Fundamentals of pediatric surgery*. Second Edition. Cham: Springer International Publishing, 2017.
- 27 Mattei P. Fundamentals of pediatric surgery. In: Mattei P, ed. *Uncommon hernias*. Cham: Springer International Publishing, 2022: 789–93.
- 28 Truong S, Pfingsten FP, Dreuw B, et al. Stellenwert der sonographie in der diagnostik von unklaren befunden der bauchwand und leistenregion. *Chirurg* 1993;64:468–75.
- 29 Draghi F, Cocco G, Richelmi FM, et al. Abdominal wall sonography: a pictorial review. *J Ultrasound* 2020;23:265–78.
- 30 Shastri N, Gilmer L. Periumbilical swelling in an infant. *Am Fam Physician* 2008;77:1151–2.
- 31 Zens T, Nichol PF, Cartmill R, et al. Management of asymptomatic pediatric umbilical hernias: a systematic review. *J Pediatr Surg* 2017;52:1723–31.
- 32 Kaur M, Grandpierre V, Oltean I, et al. Predictors of spontaneous resolution of umbilical hernia in children. *World J Pediatr Surg* 2021;4:e000287.
- 33 Bowling K, Hart N, Cox P, et al. Management of paediatric hernia. *BMJ* 2017;359:j4484.
- 34 Akkoyun I. The advantages of using Photographs and video images in telephone consultations with a specialist in paediatric surgery. *Afr J Paediatr Surg* 2012;9:128–31.
- 35 Shoukry M, Hemimy M. Versatility of ultra sound scan in paediatric epigastric hernia repair. *J Surg* 2017.